

Columbus Hospital

Great Falls, Montana

AUTOPSY REPORT

A

Autopsy No. 57-ML-79

Hospital No. Medico-legal

Name NEES, Kimberly Ann Age 17 Sex Female

Day and Hour (of death) _____ (of autopsy) 6-16-79 12:30 P.M.

Autopsy Permission Signed by: Roosevelt County Coroner L. M. Clayton III

Attending Physician _____

FINAL ANATOMICAL DIAGNOSES:

- I. Multiple blunt force impact injuries involving head and neck, with:
 - A. Extensive skull fractures.
 - B. Contusions and lacerations of brain.
 - C. Intracranial hemorrhage.

- II. Multiple superficial blunt force impact injuries involving upper extremities, mainly hands.

- III. Post mortem abrasions of left posterior thorax.

NEES, Kimberly Ann

SUMMARY:

It is reported that this seventeen year old white female was found in the water close to the bank of the Poplar River at a site near Poplar, Montana. The body was discovered at approximately 7:00 A.M. on 6-16-79, however, a pickup truck parked nearby was noted to be there several hours previously. The truck cab and ground about the area contained blood and there were drag marks on the ground from near the truck to the embankment from where the body was discovered.

Significant findings of autopsy examination include the following:

1. Death resulted from multiple blunt force type impacts to the head which caused injury to the brain and intracranial hemorrhage.
2. Other injuries involved mainly the hands and these were of defense wound type.
3. All injuries to the head, neck and extremities appear to have been acquired within a short interval of one another and just prior to death.
4. Dragging type abrasions of the posterior chest were acquired post mortem and there is no evidence to suggest that the deceased was alive when placed in the water.
5. There was no evidence of recent sexual intercourse.

NEES, Kimberly Ann

GROSS DESCRIPTION:

External Examination:

The body is accompanied by Tribal Police Officer Alfred P. Lizotte. The body is wrapped in a white sheet containing blood stains about the head area.

① The body is clothed in a V-neck blue sweater style shirt which has been pulled upward above the brassiere anteriorly, a tan brassiere in usual position, blue jean trousers buttoned at the waist and zipped up the front, white underpants with a red, green and blue patterned design, brown plastic soled shoes with laces tied and red socks. A black comb is present in a trouser pocket. All of the clothing is water soaked and there is mud over a part of the face. The sweater shirt is torn in the left axillary region and the right shoe is torn on the right side near the laces. There are no visible hairs on the clothing or on the sheet in which the body was submitted. There is a segment of fine gold chain on the sheet beneath the body.

② With clothing removed the body is that of a well developed, well nourished young adult white female measuring 159 cm. (62.5 inches) in height and weighing 53 kg. (116 pounds). The body surface is cold and exhibits no evidence of decomposition change. Rigor mortis is marked in muscles of the neck and extremities. There is only very minimal lividity over the dorsal dependent aspect of the body. The scalp and pubic hair are both brown. Recently shaven areas of hair on the lower legs contain a stubble averaging no greater than 1 to 2 mm. in length. There is no facial cosmetic material detected. Irides are gray and the pupils are round, each measuring 0.6 cm. in diameter. The mouth contains chewing gum and natural teeth appear in excellent repair. There is a healed vaccination type scar over the left upper arm laterally measuring 2.5 cm. in maximum dimension. Fingernails are clean and trimmed short and smooth. Scrapings reveal no blood or skin. There is no abnormal angulation, mobility or swelling of any extremity to suggest bony fracture.

Combing of pubic hair reveals no foreign hair. The external genital region is intact and exhibits no evidence of recent injury. The vaginal orifice is open and only tags of the hymenal ring are present about the periphery. Vaginal secretions are taken for analysis.

External evidence of recent injury is as follows:

Trunk:

There is a pale, reddish blue contusion over the left cervical region anteriorly located midway between the base of the neck and the shoulder and measuring 3 cm. in maximum dimension.

NEES, Kimberly Ann

There is a pale, reddish blue contusion on the superior aspect of the right shoulder measuring 3 cm. in maximum dimension.

There is a pale, reddish blue contusion over the right posterior thorax superiorly at the level of the superior aspect of the right shoulder which measures 4 cm. in maximum dimension. *Not drawn in.*

There is a red, linear, superficial abrasion extending transversely over the superior sacral region of the back near the midline which measures 2 x 0.6 cm. 3

There is an area of rough sliding type abrasion, reddish tan in color and containing a few minute particles of dirt over the left posterior thorax. The striations of the abrasion extend longitudinally over an area 19 cm. in length by 8 cm. in width and there are small overstretch striations superiorly. On section, there is no evidence of recent hemorrhage within the skin or subcutaneous tissue about this abrasion.

Extremities:

4 Over the right shoulder area anteriorly there is a red abraded contusion 4 cm. in maximum dimension which has a somewhat linear deeper red discoloration superiorly.

5 On the lateral aspect of the right upper arm there is a blue contusion 3 cm. in maximum dimension located 12 cm. inferior to the superior aspect of the shoulder. Near the margin of this contusion on the inferior aspect there are two small superficial red abrasions, somewhat linear and measuring 0.7 and 1.5 cm. in maximum dimension respectively. Over the dorsal aspect of the right hand there are multiple reddish blue contusions, some with superficial abrasion and extending from the wrist down over fingers two through five. These vary from 0.5 to 3 cm. in maximum dimension.

There is a pale blue contusion over the extensor aspect of the left forearm midway between the elbow and the wrist measuring 3 cm. in maximum dimension.

Over the dorsal aspect of the left hand there are multifocal areas of reddish blue contusion, some with superficial abrasion, extending from the wrist down to the distal metacarpal region and involving the proximal phalanx of the second finger. These measure up to 5 cm. in maximum dimension.

Head and Neck:

There are three deep gaping lacerations involving the forehead near the midline and toward the right side; two superiorly extending

Two people carrying her.

Not covered by a garbage bag

NEES, Kimberly Ann

transversely and one inferiorly just above the midportion of the right eyebrow extending longitudinally. All exhibit abraded and, to some extent, contused margins and all tend to be semilunar defects. All three extend deep to bone and there is palpable skull fracture of the right frontal bone beneath the longitudinal defect. These lacerations vary from 3.2 to 3.4 cm. in length.

There is a reddish blue, oval contusion on the left malar area laterally measuring 10 x 3 cm.

There are two pale blue contusions involving the left eye, one on the left lower eyelid measuring 2.5 cm. in maximum dimension and the other at the lateral aspect of the left eye measuring 1 cm. in maximum dimension.

There is a reddish blue contusion over the left frontotemporal area of the scalp at the hairline located 7 cm. superior to the left ear auricle and measuring 6 cm. in maximum dimension.

There is a superficial red abrasion on the bridge of the nose slightly to the left side of the midline and measuring 1 cm. in maximum dimension.

There is a deep gaping laceration involving the left ear and extending from the skin anteriorly into the crus of the ear helix measuring 3.5 cm. in length. There is marginal abrasion of skin about the defect and crushed cartilage beneath. Temporal bone fracture is palpable beneath the anterior aspect of the defect.

There is a reddish blue contusion of the right ear auricle within the depression adjacent to the inferior aspect of the helix which measures 1.5 cm. in maximum dimension.

At the posterior attachment of the right ear auricle to skin of the scalp there is a deep laceration extending to bone which exhibits marginal abrasion. This laceration extends longitudinally over a length of 3.5 cm.

Over the left neck region on the skin adjacent to the left ear lobe there is an oval, reddish blue abraded contusion measuring 5 cm. in maximum dimension which has a superficial semilunar laceration superiorly 1 cm. in length.

Over the posterior neck near the midline there is a reddish blue abraded contusion which extends from within the scalp hair inferiorly over an area 6 x 4 cm. Several semilunar darker red discolorations within the contusion suggest several impacts to the area.

NEES, Kimberly Ann

On the right neck posterolaterally at the hairline there is a reddish blue abraded contusion measuring 5 x 3.5 cm. which has a linear dark red discoloration superiorly.

Over the left frontotemporoparietal area of the scalp there are multiple deep lacerations, all of which appear to have abraded margins and most exhibiting a semilunar pattern. The only one which is essentially linear measures 7.6 cm. in length and is located over the left frontoparietal area superiorly. Another located adjacent to this long linear laceration is a semilunar shorter one located 4 cm. above the superior aspect of the left ear auricle and measuring 2.5 cm. in length. One is located near the midline of the superior parietal area measuring 2.2 cm. in length, three are located near the midline of the posterior parietal area varying from 1.6 to 2.6 cm. in length and three are located posterolaterally over the left parietal region varying from 1.3 to 3.2 cm. in length.

Over the right temporoparietal area there are multiple similar lacerations all with abraded and partially contused margins and most extending deep to bone. One over the right temporal area extends transversely 2 cm. above the superior aspect of the right ear auricle and measures 3.5 cm. in length. Another with an extremely irregular configuration and somewhat stellate structure inferiorly involves the mid-temporoparietal area and measures 8 cm. in length. It seems evident that several impacts have caused this one defect. The interior aspect of this defect begins 4 cm. above the superior aspect of the right ear auricle and extends nearly to the midline.

Over the occipital region of the scalp there are multiple similar lacerations all of which have abraded and partially contused borders and most extending deep to bone. One located over the right occiput laterally measures 1.2 cm. in length, two others near the midline superiorly and extending transversely measure 1.8 and 3.2 cm. in maximum dimension respectively, and still another located over the left lateral area at the approximate level of the superior aspect of the left ear auricle measures 2.2 cm. in length. Just beneath this laceration and at the approximate level of the midportion of the ear auricle there is an oval, dark red contusion measuring 3.3 x 1.6 cm.

Internal Examination:

Evidence of recent internal injury is as follows:

The scalp is reflected to reveal an extensive degree of recent hemorrhage not only immediately adjacent to the aforementioned lacerations, but throughout intervening tissue as well. The areas of hemorrhage extend down to bone and are most prominent about the deepest lacerations. There is extensive comminuted skull fracture involving an oval area of the left temporal and inferior parietal regions measuring 9.6 cm.

Hammer handle

NEES, Kimberly Ann

Fragments of bone are depressed into adjacent leptomeninges and cerebral tissue. There is also an area of depressed skull fracture in the right frontal region anteriorly measuring 2.8 x 1.6 cm. Another extensive area of comminuted and depressed skull fracture involves the right temporal region over an area 8.5 x 4 cm. Here again, depressed fragments of bone appear to penetrate the leptomeninges. A linear area of fracture is located near the midline of the occiput inferiorly and this measures 2.5 cm. in length. There is extensive intracranial hemorrhage, mainly within the subarachnoid region over the cerebral hemispheres but also, to some extent, within the subdural areas bilaterally. The brain, on removal, weighs 1,260 grams and has normal contour. There is a contusion over the right frontal region anteriorly 2.5 cm. in width and up to 0.4 cm. in depth. The largest area of contusion with superficial cerebral laceration involves the right temporal region and this measures 7 cm. in maximum dimension and up to 2 cm. in depth. Over the left temporal region there is a superficial contusion 4 cm. in maximum dimension and up to 0.8 cm. in depth. Over the left occipital region there is a linear superficial contusion measuring 4 x 0.3 cm. and extending up to 0.8 cm. in depth. The ventricular fluid is bloody throughout. Other than the aforementioned injuries to the brain, no anatomic defects are noted. The pituitary gland is unremarkable and there is no evidence of fracture to the basilar aspect of the skull.

Remainder of body organ examination:

Thoraco-abdominal cavities are opened through the usual Y-shaped incision to reveal organs that maintain normal anatomic contour and relationship. At this time approximately 60 ml. of blood is aspirated from the heart and retained for laboratory analysis. The urinary bladder is empty. In the stomach there is semi-liquid gray material estimated at approximately 200 ml. which contains no identifiable food substance. This gastric contents has no characteristic odor to suggest toxic substance present. All thoraco-abdominal organs are removed and dissected in usual manner and they exhibit no evidence of recent injury or natural disease. The lower tracheobronchial airway is patent and empty. The airway and lung parenchyma exhibit no evidence of water aspiration. Internal genital organs are those of a young adult female and unremarkable. The endometrial canal is empty. Body organ weights are as follows: Heart 230 grams, lungs 710 grams, liver 1,250 grams, spleen 70 grams, right kidney 80 grams and left kidney 90 grams.

At this time the thoracic skin is reflected upward to the level of the chin exposing the neck structures anterolaterally. Here there is no evidence of recent injury. The hyoid bone, larynx and upper trachea are intact. The posterior pharynx and airway are empty.

95%
at she
was not
choked

NEES, Kimberly Ann

MICROSCOPIC:

Sections (A) taken from deep tissue of the left scalp adjacent to an area of laceration reveal recent hemorrhage but no inflammatory cell infiltrate.

Sections (B) representing skin of the left scalp from an area marginating the superficial aspect of a laceration reveal recent hemorrhage but no inflammatory cell infiltrate.

Sections (C) taken from the left temporalis muscle reveal recent hemorrhage and no inflammatory cell infiltrate.

Sections (D) representing a laceration area of the right scalp reveal recent hemorrhage and again, no inflammatory cell infiltrate.

Sections (E) taken from the contused area of the left cheek reveal extensive recent hemorrhage but no inflammatory cell infiltrate.

Sections (F) representing an abraded contusion on the anterior aspect of the right shoulder reveal abraded epidermis with recent hemorrhage within dermis and subcutaneous fat. No inflammatory cell infiltrate is noted.

Sections (G) representing an abraded contusion on the dorsum of the left hand reveal recent hemorrhage and no inflammatory cell infiltrate.

Sections (H) representing an abraded contusion on the dorsum of the right hand reveal recent hemorrhage and no inflammatory cell infiltrate.

Sections (I) representing an abraded area from the posterior aspect of the left thorax reveal superficial epidermal abrasion, but no vital reaction. Within the abraded epidermis there is foreign debris embedded.

Organ tissues examined including those of the brain, heart, lungs, liver, spleen, pancreas, adrenals and kidneys reveal changes consistent with the anatomic diagnoses.


57-ML-79

NEES, Kimberly Ann

ADDITIONAL LABORATORY EXAMINATIONS:

- I. Heart blood:
 - A. Ethyl alcohol content - 0.03 gm/dl.
 - B. Blood Grouping - Type O Rh CCD-ee.

- II. Vaginal secretions:
 - A. Stained smears - No spermatozoa seen.
 - B. Prostatic acid phosphatase - 123 I.U.



J. Pfaff, Jr., M.D.
Forensic Pathologist

JP:jf

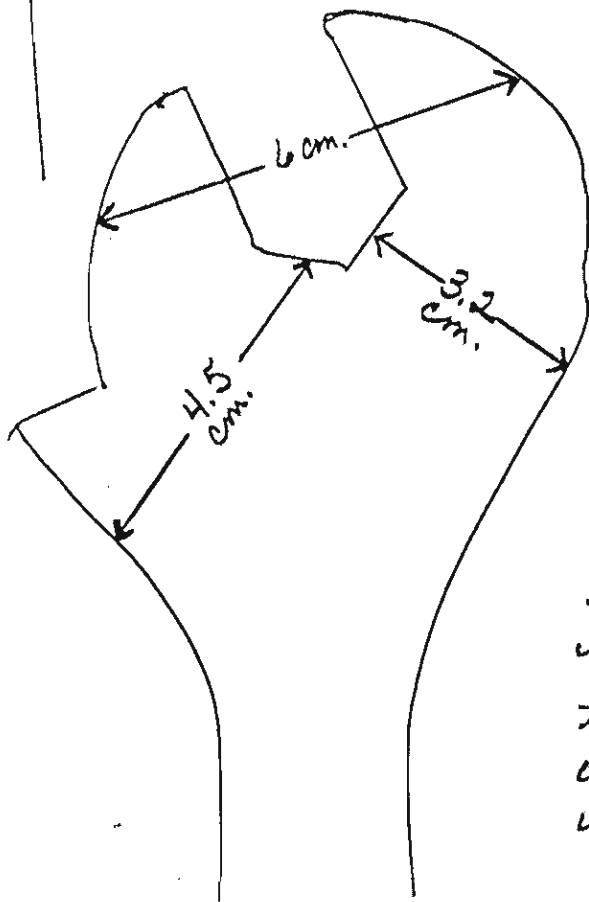
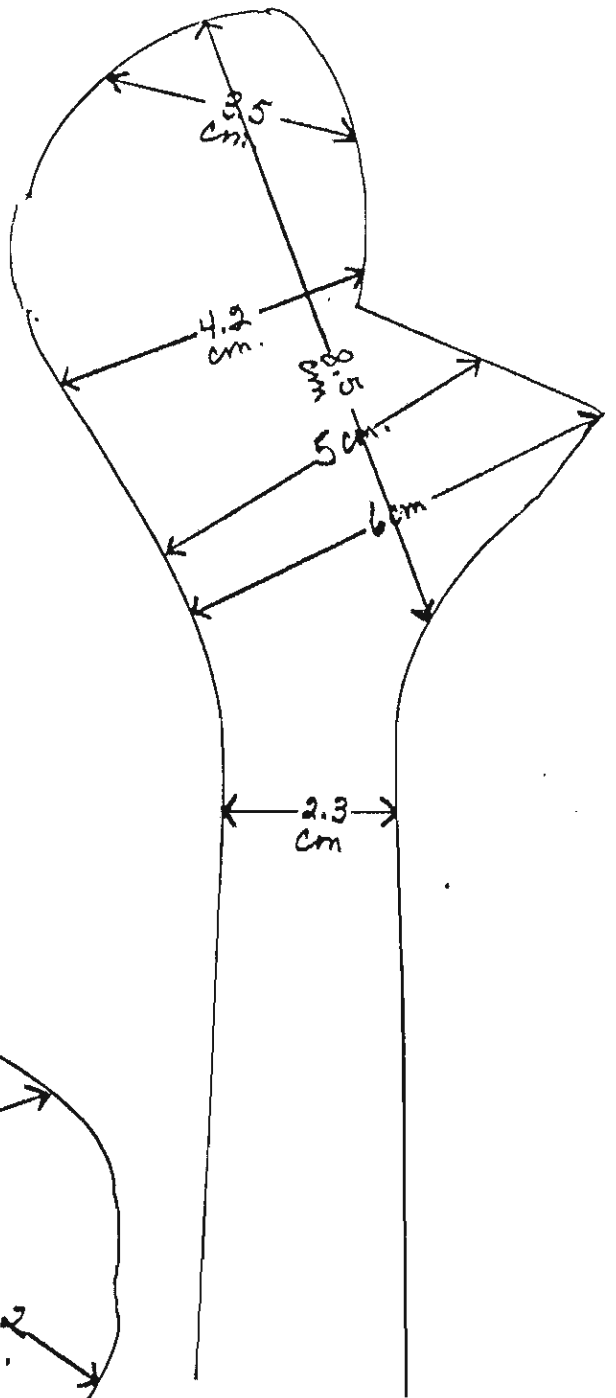
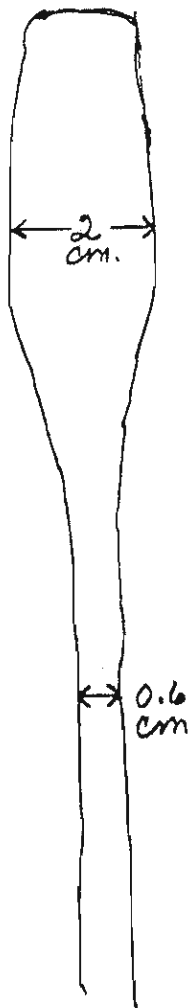
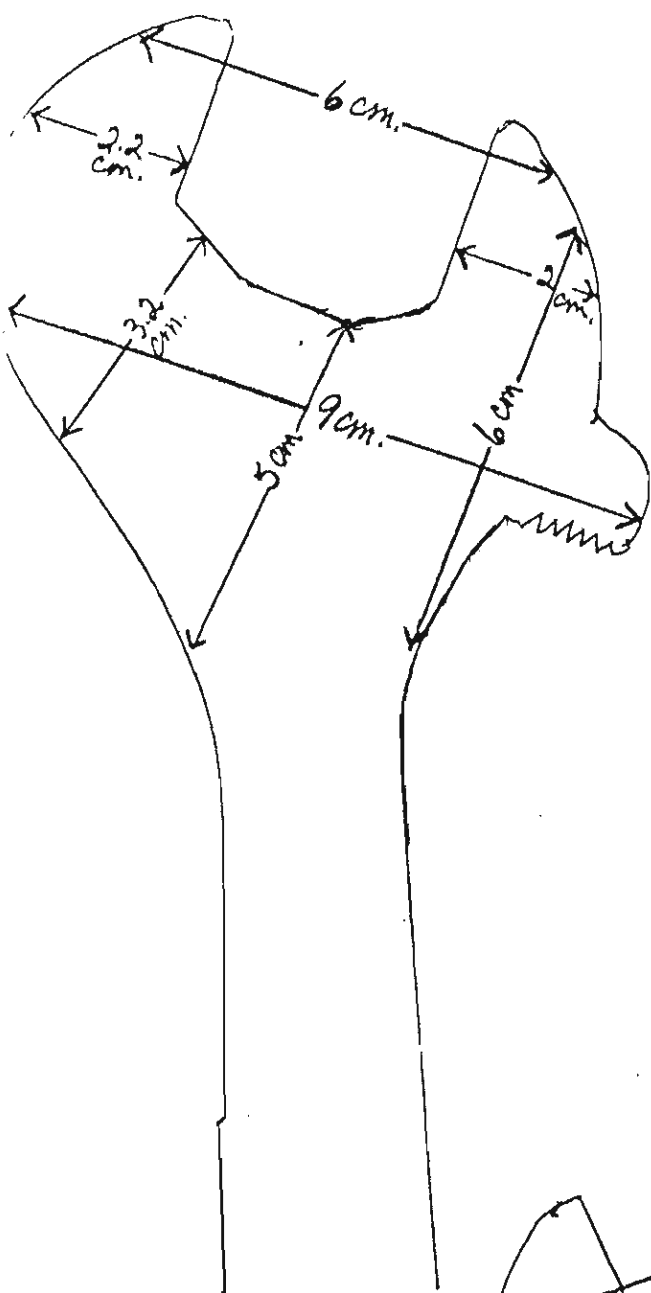
AUTOPSY PERMIT

I HEREBY GRANT Dr. John Pfaffpermission to
(Complete
make a (Trunk postmortem examination of the remains of my
(Head
known as Kimberly Ann Nees), and to remove organs or parts of organs, if necessary,
for further study in order to determine the cause of death.

Meriam Anderson
Witness

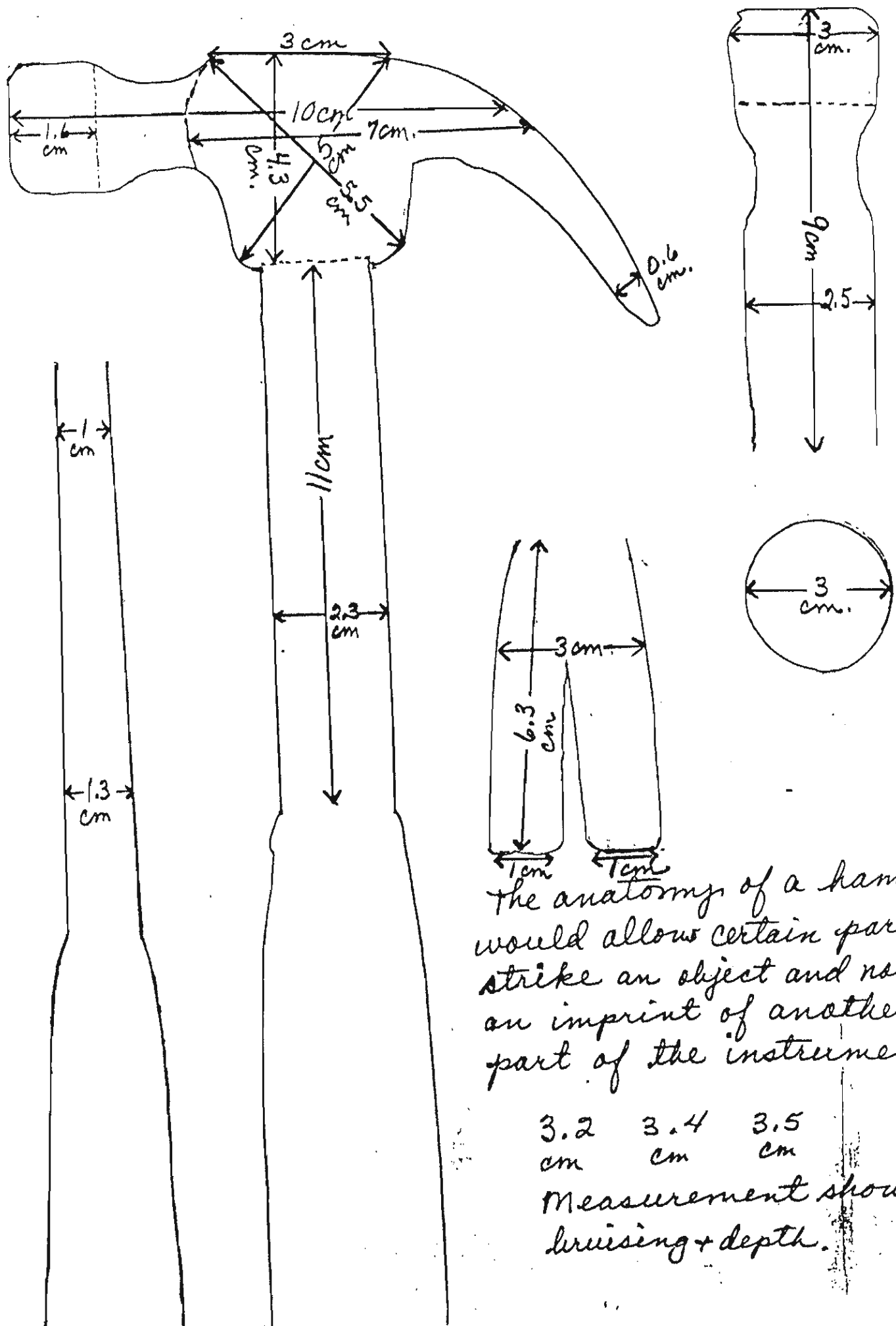
F. M. [Signature]
Roosevelt County Coroner

Quincy 14, 1979
Date



12"
Crescent
Wrench

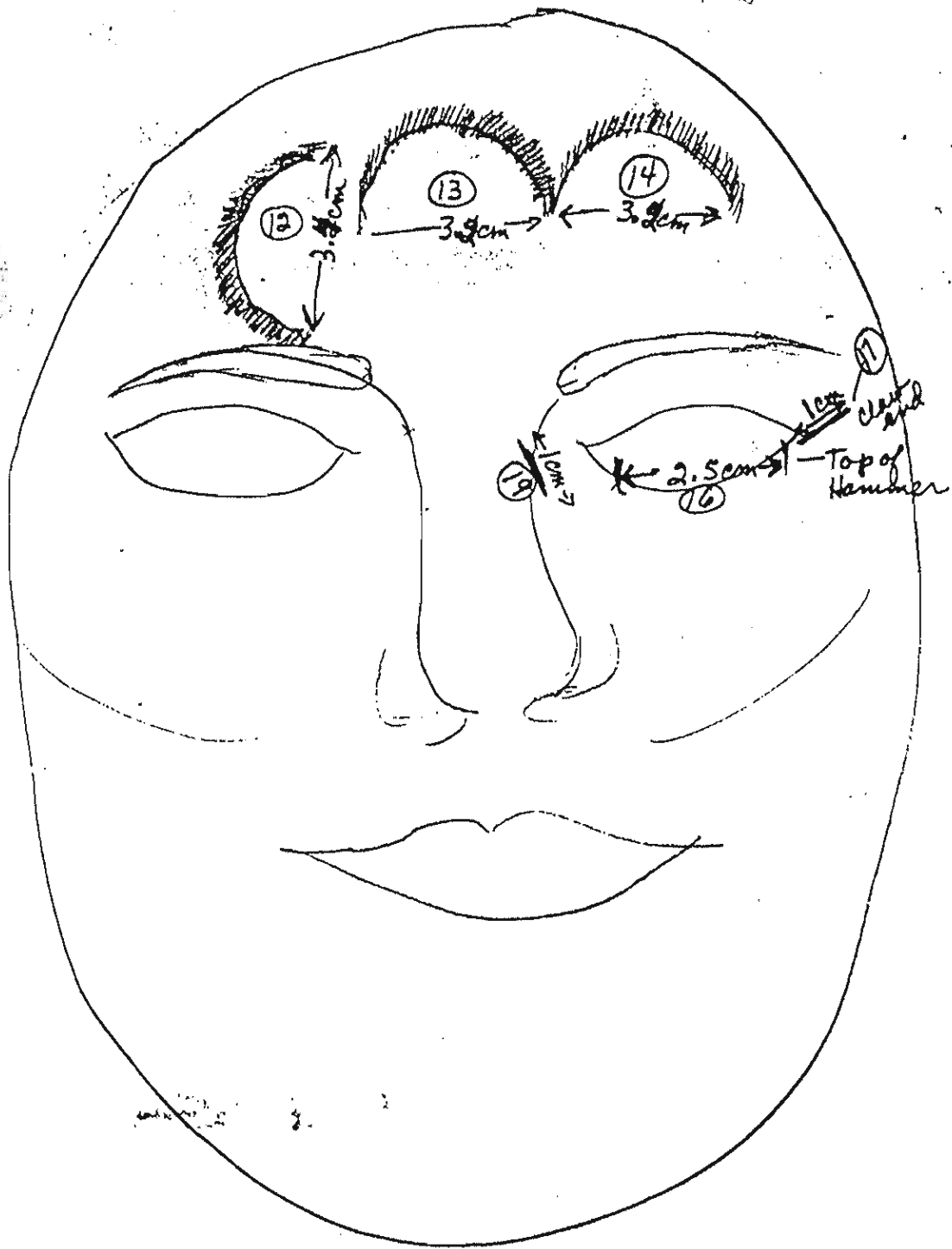
Any part of this
wrench would have
left complete imprint
marks on the body
to have matched the
wound measurements
in the autopsy report.




The anatomy of a hammer would allow certain parts to strike an object and not leave an imprint of another part of the instrument.

3.2 cm 3.4 cm 3.5 cm

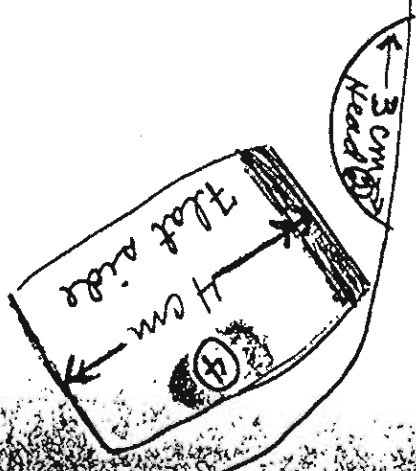

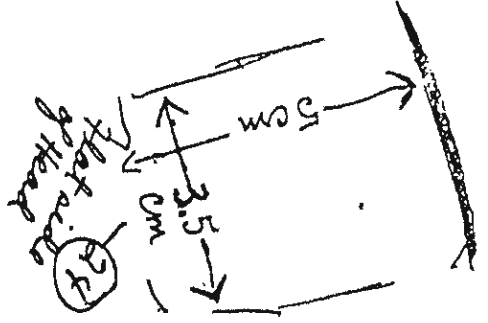
Measurement shows bruising + depth.

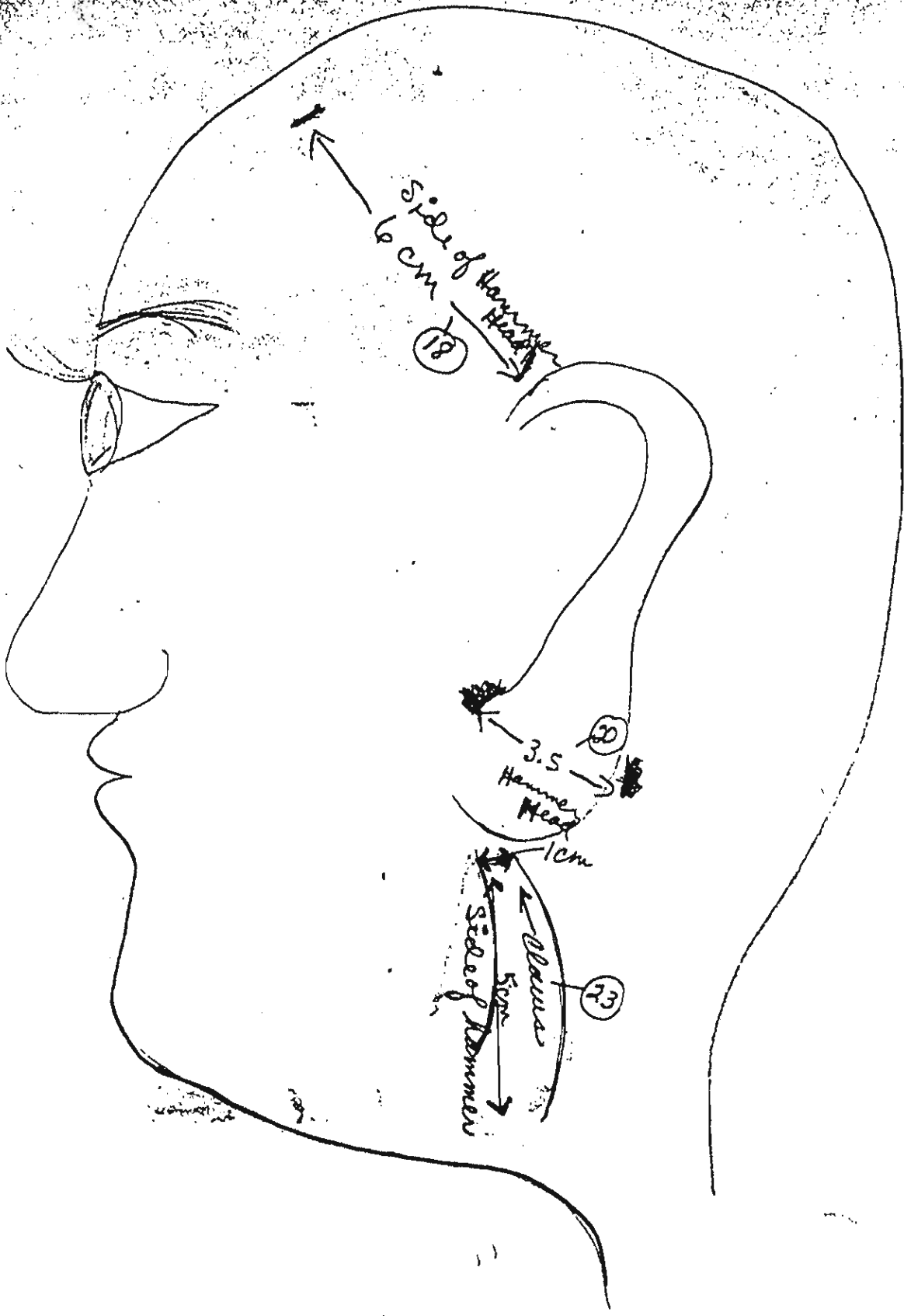






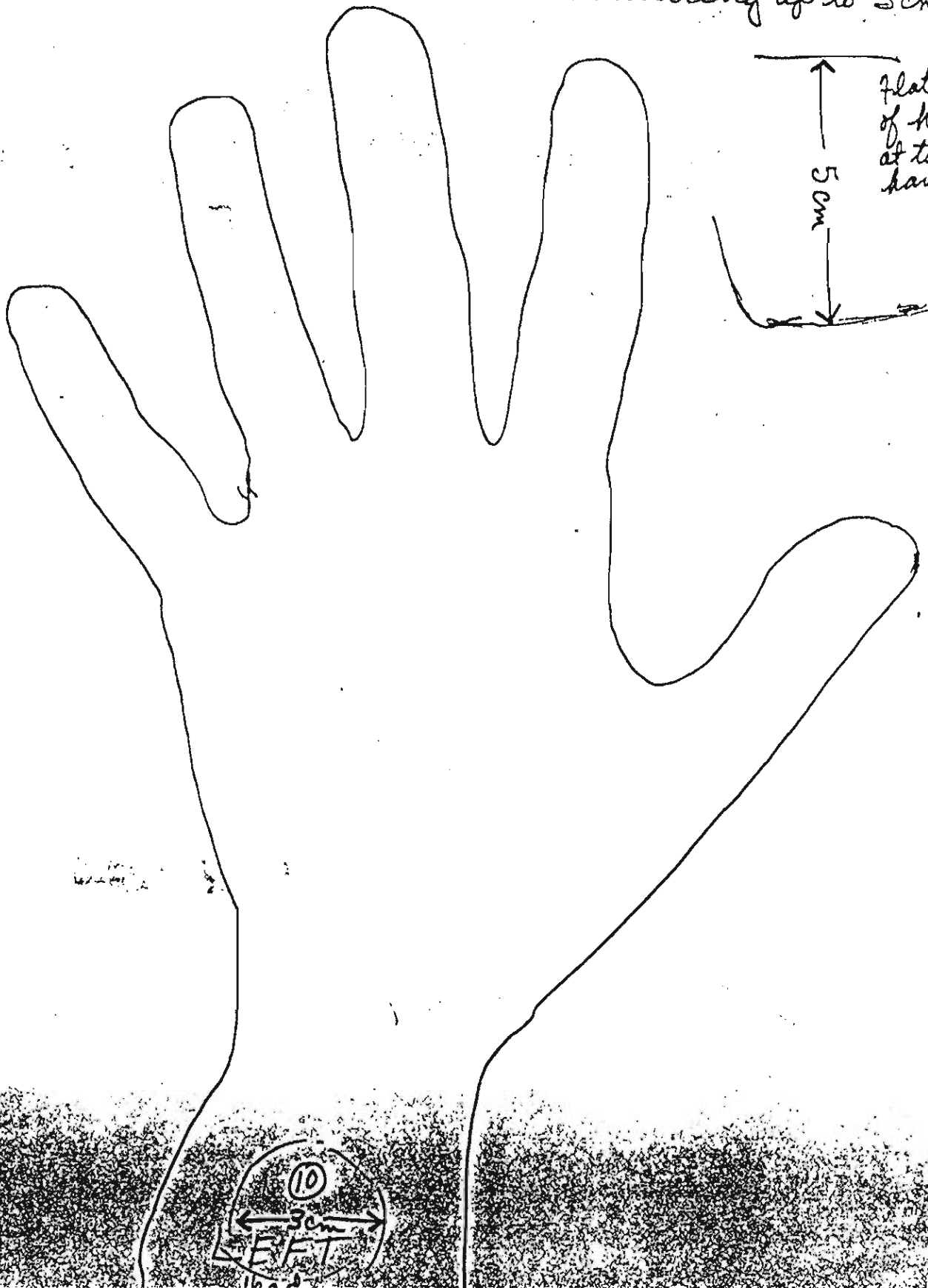
BACK





⑪

Multifocal areas of reddish blue contusion down from wrist down to end of little finger and second fingers measuring up to 5cm.



flat side
of head
at top of
handle

5cm

10

5cm

LEFT

⑧ and ⑨

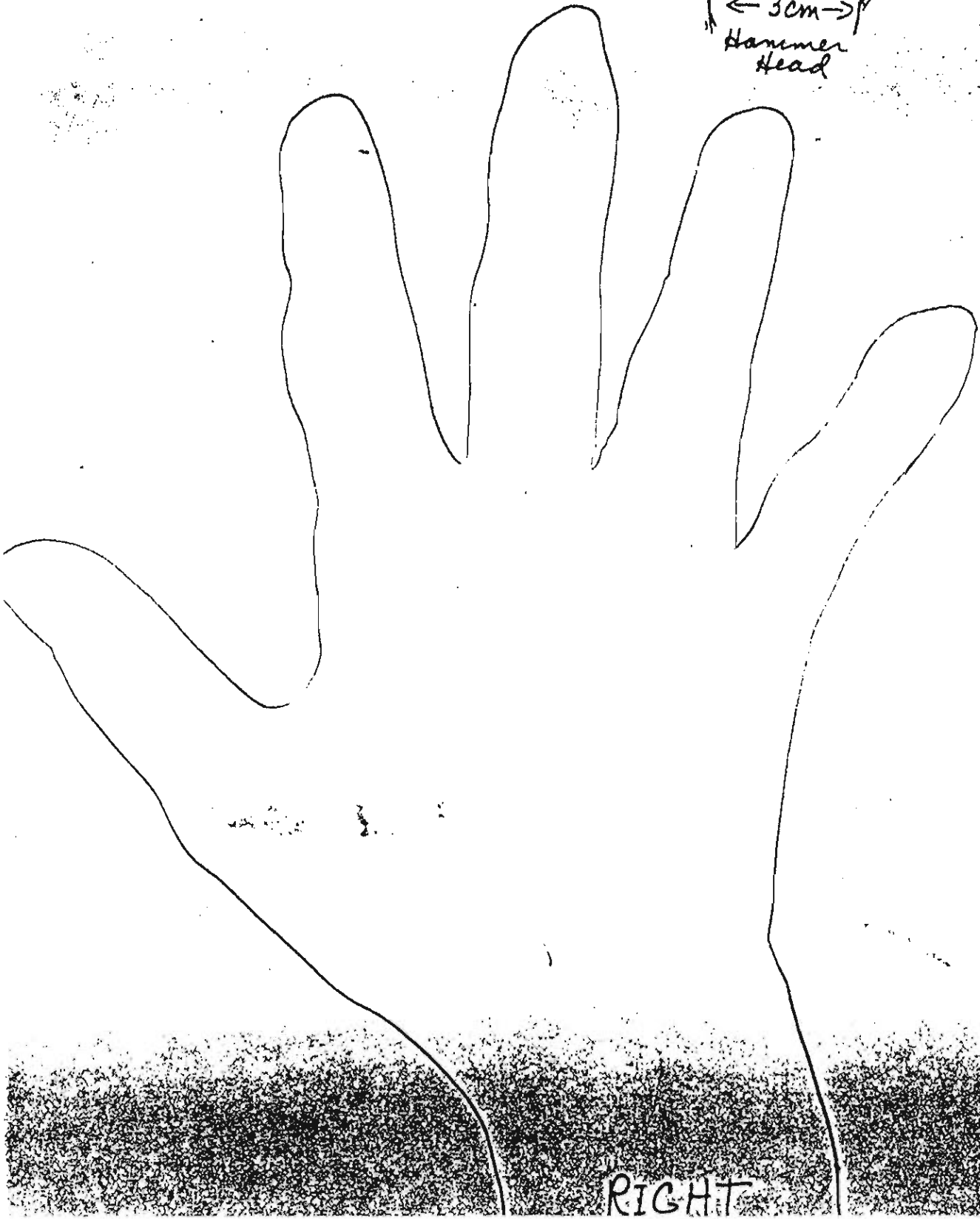
Multiple reddish blue contusions
varying from 0.5 to 3 cm. in dim.

Claws

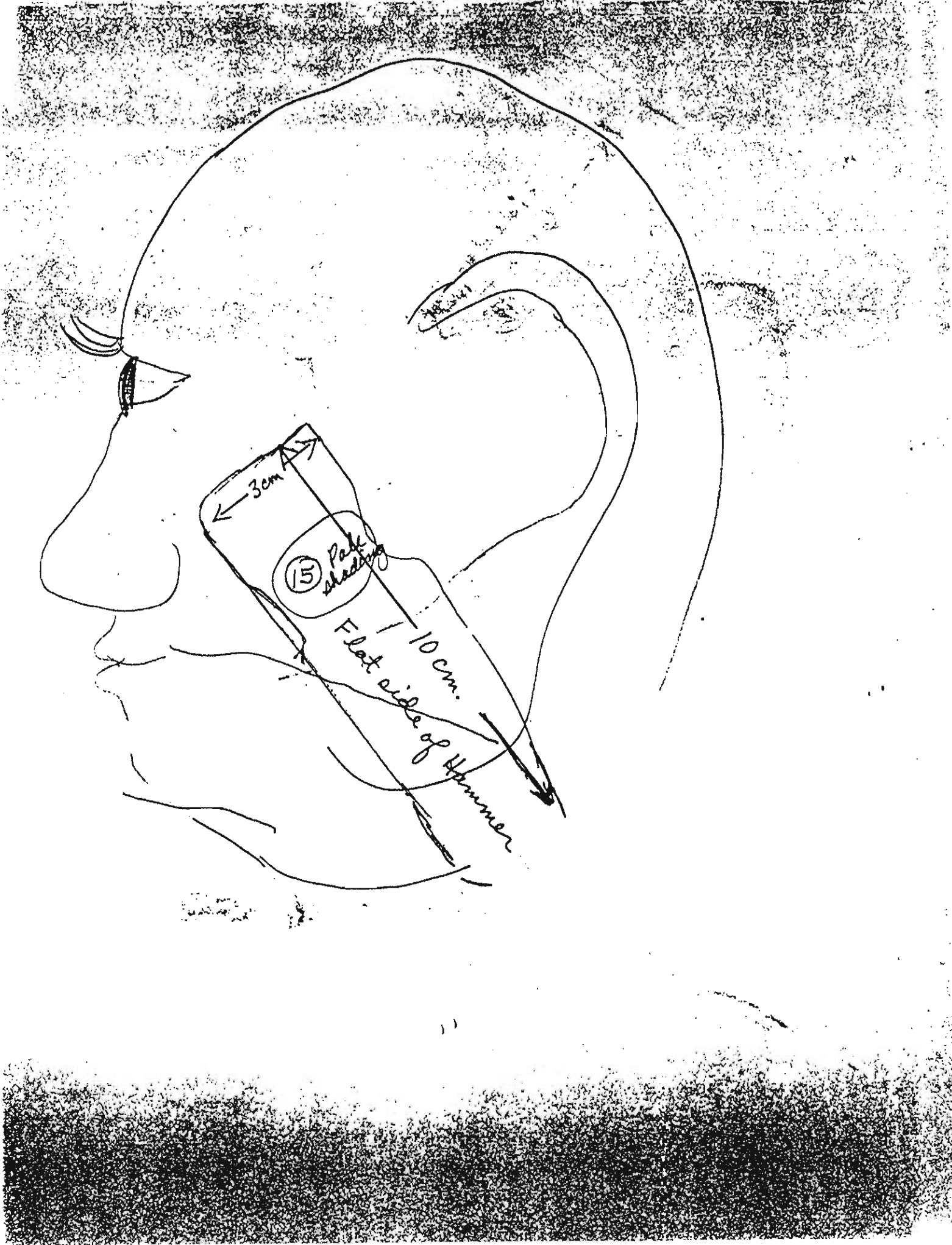
0.5cm

← 3cm →

Hammer
Head



RIGHT



15 Poke shading

3cm

10 cm.

Flat side of Hammer



STATE
OF
MONTANA

DIVISION OF FORENSIC SCIENCE

DEPARTMENT OF JUSTICE

275 West Front Street, Missoula, MT 59802 (406) 728-4970

A-1

Ronald L. Rivers, M.D.
State Medical Examiner

Arnold B. Melnikoff
Laboratory Bureau Chief

Dawn M. Kangas
Administrative Assistant

November 4, 1983

H.c

Ron Wilson, Undersheriff
Roosevelt County Sheriffs Office
Box 280
Wolf Point, Montana 59201

Re: Victim: Kemberly Ann Noes
Suspect: Barry A. Beach

Dear Sir:

Enclosed is the analysis report covering the material submitted for chemical analysis on October 12, 1983 under LAB#CUB2 & CUB3-101283.

We are returning the submitted samples under separate cover via United Parcel Service.

If we can be of any assistance in the future, please do not hesitate to contact us.

Sincerely,

DIVISION OF FORENSIC SCIENCE
Criminalistics Laboratory

A handwritten signature in cursive script, appearing to read "Arnold B. Melnikoff".

Arnold B. Melnikoff
Bureau Chief

ABM/ms
enc.

DIVISION OF FORENSIC SCIENCE
275 WEST FRONT STREET
MISSOULA, MONTANA 59801

DATE RECEIVED: October 12, 1983

ANALYSIS REQUESTED BY: ROOSEVELT COUNTY SHERIFFS OFFICE
DESCRIPTION AND WEIGHT OF ITEM(S) RECEIVED: The following:

Beach CUB2 A1-A8 - Sample A-1 - Sealed paper with known head hair for
CUB2 B - Sample A-1-A - hairs present were mounted on eight slides
shirt CUB2 C1-C3 - Sample A-1-B - Hair from (Nee's levi's) in sealed envelope
CUB2 D - Sample A-1-C - Hair from (Nee's shirt) in sealed envelope
CUB2 E - Sample A-1-D - Sealed envelope with hair from victim's
shirt CUB2 F1-F11 - Sample A-1-E - Sealed envelope with hair from Nee's
shoe prepared of the hair present.
LAB I.D. NUMBER: LAB#CUB2-101283 and LAB#CUB3-101283
CASE INVOLVED: Suspect: Barry Allen Beach Victim: Kimber

ANALYSIS RESULTS: ITEMS RECEIVED CONTINUED:
CUB3 A1-A10 - Samples A-10 - Sealed evidence bag with hair from draw
blood present. Ten microscope slides
hair present.

ANALYSIS RESULTS:

THE EIGHT SLIDES IN A1-A8 WERE EXAMINED MICROSCOPICALLY AND USED AS KNOWN
BARRY BEACH'S HEAD HAIR.

THE ONE SUSPECTED HAIR PRESENT WAS EXAMINED MICROSCOPICALLY AND FOUND TO
FIBER - NOT HAIR.

THE THREE HAIRS PRESENT IN C1-C3 WERE EXAMINED MICROSCOPICALLY WITH THE FOLLOWING
ONE SLIDE CONTAINED PUBIC HAIR - C1. SINCE NO PUBIC HAIR STANDARDS WERE
WAS NOT POSSIBLE TO IDENTIFY THE POSSIBLE SOURCE.

ONE SLIDE CONTAINED BLACK CAT HAIR - C2.
ONE SLIDE CONTAINED HEAD HAIR CHARACTERISTIC OF THE VICTIM'S HEAD HAIR -

NO HAIR WAS FOUND TO BE PRESENT IN E.

THE ELEVEN SLIDES IN F1-F11 WERE EXAMINED MICROSCOPICALLY. ALL ELEVEN SLIDES CONTAINED HEAD HAIR CHARACTERISTIC OF KIMBERLY NEE'S HEAD HAIR.

THE TEN SLIDES IN CUB3 A1-A10 WERE EXAMINED MICROSCOPICALLY AND WERE USED AS KNOWN STANDARDS OF KIMBERLY NEE'S HEAD HAIR.

4c
Date: November 4, 1983

Arnold Melnikoff

Arnold B. Melnikoff

None of the hair matched Barry A. Beach